

## Dilated cardiomyopathies in dogs



Dilated cardiomyopathy (DCM) is primary disease of the muscle of the heart, characterized by a progressive decline in the contractility of the ventricles, dilation of all the cardiac chambers, leading to congestive heart failure (CHF), arrhythmias, and death. Histopathology of the cardiac muscle (myocardium) reveals necrosis of cardiac cells, scar tissue (fibrosis), and sometimes replacement of the cardiac muscle cells by fat. Interestingly enough, there is very little inflammation.

### Prevalence and demographics

#### Adult-Onset DCM

The overall prevalence of DCM in the general canine population is 0.5-1.1%. This cardiopathy represents 11% of all cardiac diseases in dogs. The prevalence of this disease is 5 times greater in pure-bred dogs (0.65%), than in mixed-breed dogs (0.16%). Large breed dogs are far more susceptible to DCM than small breed dogs. Amongst these breeds, the most predisposed are the Scottish Deerhound, the Doberman Pinscher and the Irish Wolfhound, followed closely by the Great Dane, the Boxer and the St Bernard. Then, one can cite the Afghan Hound, the Newfoundland, the English Sheepdog, the English Cocker spaniel, the American Cocker spaniel, the Labrador, and the Golden Retriever (Figure 1).

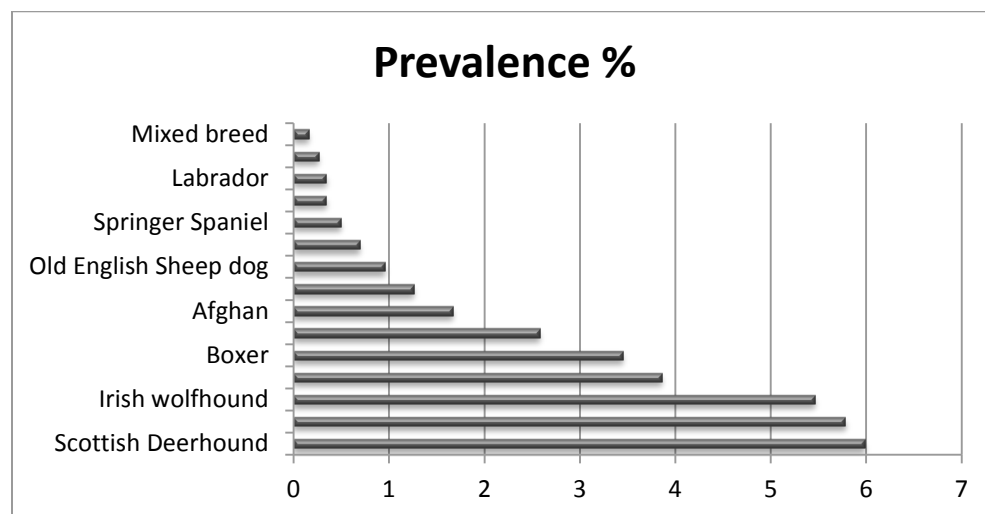


Figure 1: Prevalence of dilated cardiomyopathies in various breed of dogs. Adapted from Sisson DD, Thomas WP. Myocardial diseases. In Ettinger SJ, Feldman EC (eds): Textbook of Veterinary Internal Medicine. 4<sup>th</sup> ed. Philadelphia, WB Saunders, 1995, p. 995.

This disease typically affects adult dogs (median age 4-8 years). Males are affected twice as much as females.

### **Juvenile DCM**

A juvenile form of DCM has been described in a family of Portuguese Water dogs, with puppies dying of CHF at 4 months of age, as well as in Toy Manchester Terriers. The transmission appears to be homozygous recessive.

## **Etiology and pathogenesis**

### **Genetic anomalies**

The breed and familial predisposition noted support a genetic aetiology of DCM in some breeds, with a possible autosomal dominant pattern of transmission. Many different genetic anomalies have been identified in humans, mice, and sometimes dogs with DCM. For instance, dystrophin is part of a multiprotein complex that anchors the cardiac muscle cells to the extracellular matrix. This anchoring allows effective contraction. Mutations in dystrophin genes have been shown in Golden Retrievers with Duchenne's muscular dystrophy. Anomalies of other genes encoding cytoskeletal proteins have been shown in mice and humans with DCM. In Doberman Pinschers, deletion of the gene encoding for the pyruvate dehydrogenase lipoamide kinase isozyme 4 (PDK4), a mitochondrial enzyme, has been associated with DCM, but other genes may be involved as well. In Boxers affected from a specific form of cardiomyopathy (arrhythmogenic right ventricular cardiomyopathy or ARVC (see below)) a deletion of the gene encoding for striatin, a protein of the junction between the cardiac muscle cells has often but not always been identified. See also [genetic testing](#).

### **Infectious diseases**

The paucity of inflammatory changes in dogs with DCM argues against an infectious aetiology in most cases. However, there are 2 known causes of infections leading to myocarditis and DCM in dogs: parvovirus infection in young puppies and Trypanosoma Cruzi infection (Chagas disease) in dogs leaving in the Southern United States).

### **Biochemical anomalies**

- Anomalies of the mitochondrial activity and of the calcium flux:

A number of biochemical anomalies have been detected in the myocardium of patients with DCM. They include anomalies of the function of the mitochondria (the organelle of the myocardial cell responsible for the production of energy), and anomalies of the calcium (an ion critical for the interaction of contractile fibres in the cardiac muscle cells) inflow and outflow. In Dobermans, an impaired production of ATP (the molecule bringing energy to the cell) has been shown.

It is not clear whether these anomalies are the cause or the consequence of myocardial failure.

- Carnitine deficiency:

Carnitine plays an essential role in transporting long-chain free fatty acids into the inner mitochondrial membrane for energy production. Lack of carnitine deprives the mitochondria of fuel to create energy (in the form of ATP). L-Carnitine also acts as detoxifying agent, binding toxic metabolites resulting of the mitochondrial activity and transporting them outside the mitochondria.

Decreased myocardial L-carnitine concentrations have been shown in 50-90% dogs with DCM, including Boxers, Doberman, Samoyeds, American Cocker spaniels. These dogs had however normal plasma carnitine concentrations. Response to carnitine supplementation has been variable. It is now generally accepted that low myocardial level of carnitine is not a primary cause of DCM, but most likely a consequence of myocardial failure.

- Taurine deficiency:

Taurine is the most abundant amino-acid in the heart and is thought to regulate intracellular calcium kinetics. It also eliminates oxygen free radicals in myocardial cells, thereby protecting integrity of cell membranes and vital organelles. Taurine deficiency, with a low plasma taurine level has been initially documented in American Cocker Spaniels. In the MUST clinical trial, the contractility of the heart of these dogs improved significantly after supplementation with both taurine and carnitine for at least 4 months. Since then, taurine deficiency but has been documented in 17% of dogs with DCM, mostly American and English Cocker Spaniels, Springer Spaniels, Labrador, Golden retrievers, German Shepherds. Of interest is the documentation of an association between taurine deficiency and DCM in Newfoundlands. Taurine deficiency has also been found in dogs with cystine / urate bladder stones, including English Bulldogs, Dalmatians, Dachshunds, French Bulldog and Newfoundland. DCM was present in half of these dogs. Improvement of the cardiac contractility was seen with carnitine or taurine + carnitine supplementation. Low protein, vegetarian diets, and sometimes lamb-based diets may facilitate taurine deficiencies in dogs.

Because of the variable response of dogs with low plasma taurine and DCM to taurine supplementation, the real causative role of this amino-acid in the pathogenesis of this disease remains unclear.

- Toxins:

One of the most known drug-induced DCM in humans and dogs is the doxorubicin cardiotoxicity. Doxorubicin is a chemotherapeutic agent used in many cancer treatment protocols. Dilated cardiomyopathy, sometimes fatal, may occur after the 4<sup>th</sup> or 5<sup>th</sup> administration of this drug.

- Immunological causes:

Autoantibodies to various components of the myocardium have been shown in dogs with DCM. As above, it is not clear whether these antibodies are the cause or the consequence of cellular damage.

- Sustained periods of fast heart rate (tachycardia):

Heart failure with myocardial failure can be induced by prolonged periods of fast heart rate (tachycardia).

## Natural history

### Asymptomatic phase

There is a long phase without symptoms, which may last several 2-3 years. During that phase, the heart dilates progressively and its contractility declines. This phase is also called the occult phase.

In some breeds, arrhythmias may be present: ventricular arrhythmias in Dobermans and Boxers, and atrial fibrillation in Irish wolfhounds.

### Congestive heart failure

Once the deterioration of the myocardial contractility has reached a critical state, fluid accumulation occurs, leading to congestive heart failure (CHF). The most common form of CHF is left heart failure, with fluid build-up in the lungs: pulmonary oedema. The symptoms can occur suddenly or progress over several weeks. They include nocturnal cough, dyspnea and exercise intolerance. Less frequently, right heart failure may be observed with fluid accumulation in the abdomen (ascites) or in the chest cavity, around the lungs (pleural effusion). Bi-ventricular failure has been observed in 25% of Dobermans going into CHF (pulmonary oedema, ascites  $\pm$  pleural effusion and peripheral oedema).

With chronic CHF, marked weight loss with muscle wasting (cardiac cachexia) may occur.

### Syncopes, sudden death

Cardiac arrhythmias may lead to episodic weakness, fainting (syncope), collapse, and even sudden death due to ventricular fibrillation. This is especially common in Dobermans and Boxers: 20 to 30% of these will die suddenly, often after the 1<sup>st</sup> or 2<sup>nd</sup> episode of collapse, without ever going into CHF (Figure 2).

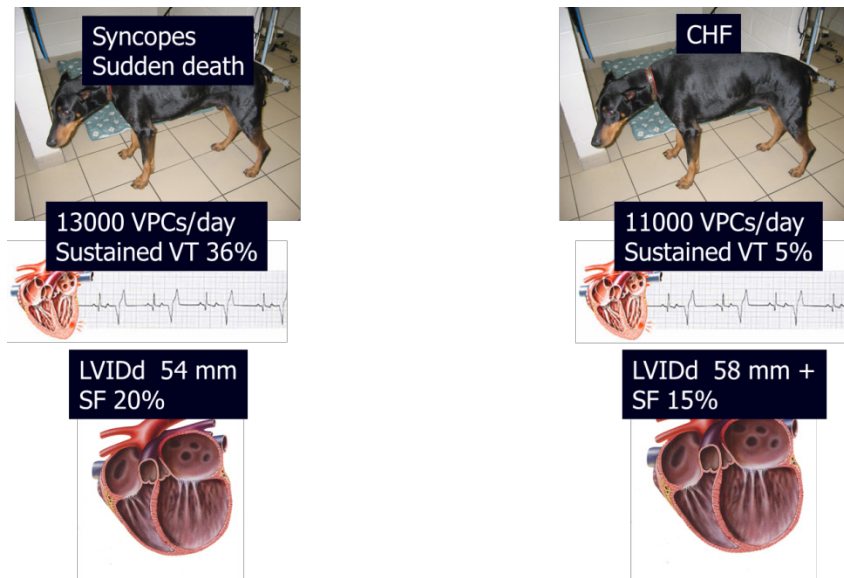


Figure 2: The 2 types of outcome in Dobermans with DCM. The syncope/sudden death group (left) is characterized by a high number of daily ventricular premature beats (VPC), runs of ventricular tachycardia (VT), and only a mild cardiac dilation and dysfunction. The CHF group (right) has also a high number of daily VPCs, not too much VT, but a higher degree of cardiac dilation and dysfunction.

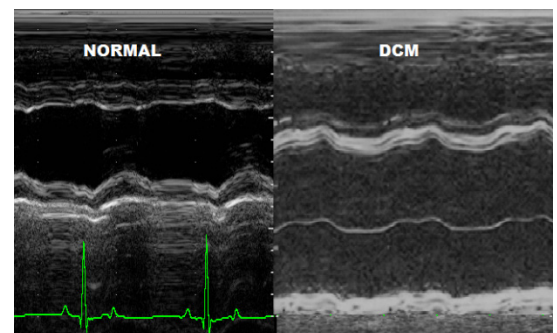
## DIAGNOSIS

### Detection of occult cases

The detection of DCM in asymptomatic dogs is difficult, because they precisely have no symptoms. Auscultation may sometimes provide a clue when a murmur, a third heart sound, or an arrhythmia is heard, but this not always the case, especially in the early stages.

- Echocardiography  
Echocardiography (cardiac ultrasound) remains the gold standard to diagnose occult DCM. The criteria of diagnosis include dilation of the left sided cavities (left ventricle and atrium), as well as diminished indices of ventricular contractility (the main ones being the shortening fraction ( $N > 25\%$ ) and the ejection fraction ( $N > 60\%$ )). As the disease progresses, the changes are becoming more obvious (Figures 3 and 4). In breeds highly predisposed to DCM like Dobermans, a yearly cardiac ultrasound is recommended.

Figure 3: Echocardiogram showing the left ventricle in a normal dog (right) and in a dog with DCM (left). One can note the marked difference in contractility between these 2 dogs.





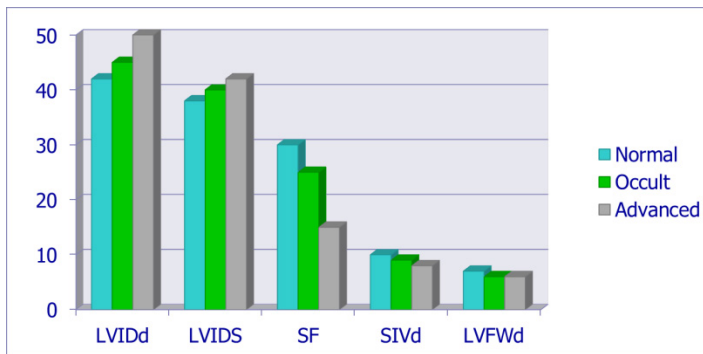


Figure 4: Echocardiographic changes in occult DCM in Dobermans. One can see the progressive increase in the left ventricular dimensions (LVIDd, LVIDs), decline in the shortening fraction (SF), and decrease in the ventricular walls thickness (SIVd, LVFWd).

- Holter

The detection of ventricular arrhythmias in Dobermans and Boxers by 24 hours ECG recordings (Holter) is also a useful screening tool for DCM in these breeds. Any count > 100 VPC/day is considered abnormal and should warrant an echocardiographic examination (Figure 5).




Figure 5: Holter recording (1 hr/page) in a Golden retriever with DCM. Ventricular premature beats (arrows) are present. One can count 64 VPC/hr on this page.

The case of the Boxer warrants a specific discussion. In this breed, the cardiomyopathy has specific characteristics and is called arrhythmogenic right ventricular cardiomyopathy (ARVC), because it affects the right ventricle (as opposed to the entire heart in the other breeds). There is right ventricular myocardial atrophy with fibro-fatty replacement of the myocardial cells. The disease is progressive and will eventually involve, but only at later stages, the left ventricle (Figure 6)

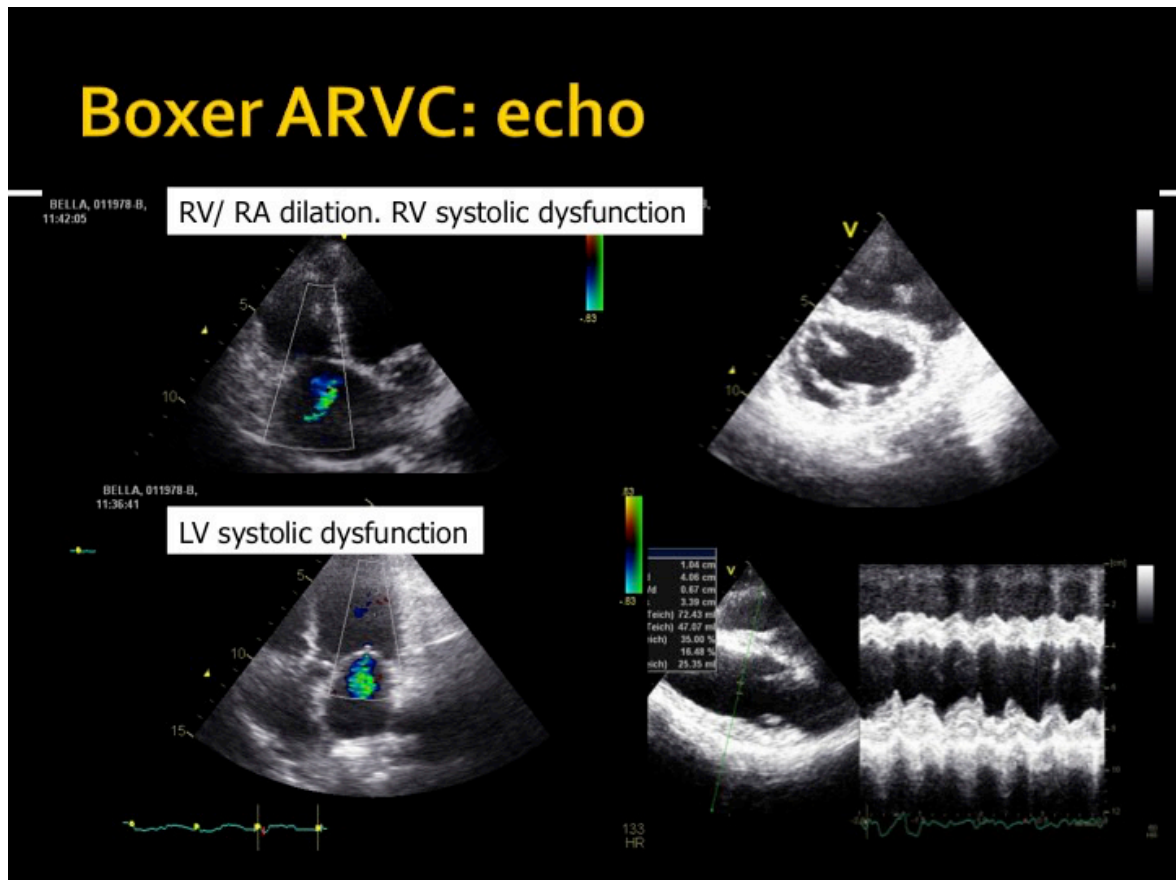


Figure 6: Echocardiographic findings of Boxer ARVC. RV: right ventricle, RA: right atrium, LV: left ventricle.

It is characterized by numerous ventricular premature beats originating from the right ventricle. Right ventricular and atrial dilation may or may not be present. The mode of transmission is autosomal dominant. The genetic anomaly associated with this disease is a deletion of the gene coding for striatin (a protein of the junctional apparatus between the cardiac muscle cells: the desmosome).

There are 3 main clinical forms: the arrhythmic form without symptoms, the arrhythmic form with syncope  $\pm$  sudden death, and the CHF form with marked impairment of the cardiac contractility (Figure 6). In the first 2 forms, the heart may still look normal on echocardiography.

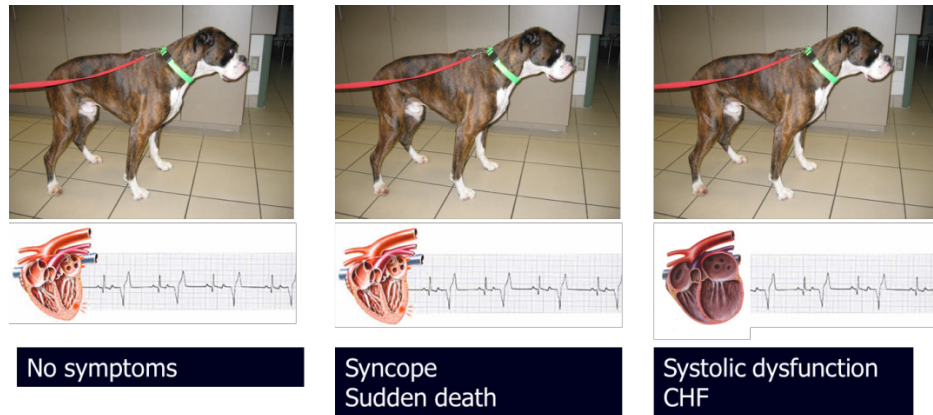


Figure 7: The 3 forms of Boxer arrhythmogenic right ventricular cardiomyopathy.

The Holter is a good screening tool to detect the arrhythmias, but may not allow to distinguish the Boxers in which the arrhythmias will never lead to symptoms from those at risk of fainting or sudden death (Figure 8). A total of VPC > 3000/day is a clear indication of risk.

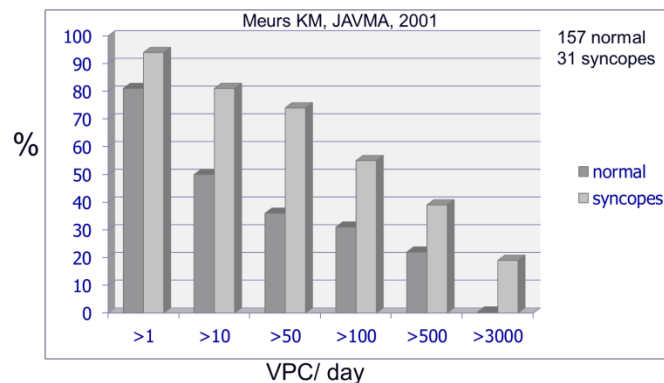


Figure 8: Holter findings in asymptomatic "normal" and fainting Boxers.

- **NT-proBNP**  
Recently, a blood test measuring the level of a substance produced by the heart called BNP has become available. Levels of BNP will increase with the presence of heart disease, and will go up even further with CHF. False positives are not uncommon, however, requiring the confirmation by other tests such as echocardiography.
- **Heart failure**  
As mentioned above, dogs in CHF develop fluid retention either in the lungs or the body cavities. This will lead to breathing difficulties, with or without coughing. Abdominal distension will appear in cases of ascites. Exercise intolerance will be noted. Decreased



appetite may also be present. The physical examination will reveal cardiac and pulmonary auscultatory anomalies, weak pulses, and poorly perfused mucous membranes. The presence of fluid either in the lungs, the chest cavity or the abdomen can be readily confirmed by radiography. Electrocardiography is indicated when the heart rate is irregular and helps diagnose which type of arrhythmia is present: atrial fibrillation or ventricular arrhythmias. Echocardiography, as discussed above, will reveal the decreased contractility of the heart.

## Treatment

### **Asymptomatic dogs**

The goal of instituting therapy in asymptomatic dogs is to slow the progression of the disease and delay the onset of CHF. Another goal is also to reduce the risk of syncope or sudden death in dogs with arrhythmias (see below). Drugs that are inhibiting the production of substances leading to the constriction of blood vessels such as angiotensin and aldosterone: the angiotensin-converting-enzyme inhibitors or ACEI (Benazapril, enalapril, ramipril) have been shown to prolong the asymptomatic phase in humans and Dobermans with DCM. Pimobendan has also been proven to be effective in delaying onset of CHF in Dobermans with occult DCM. Other medications such as beta-blockers have also been advocated, but data proving their efficacy is lacking so far, especially in dogs.

### **Congestive heart failure**

Once CHF is present, diuretics (drugs enhancing the production of urine) are necessary to relieve the congestive symptoms. Typically, furosemide is used in combination with the ACEI drugs. In addition, drugs stimulating the contractility of the heart, such as Pimobendan, have been shown to improve the clinical response and the survival, especially in Dobermans. Other agents such as spironolactone, which blocks aldosterone, have recently been shown to be beneficial as well.

### **Arrhythmias**

Antiarrhythmics are used either to slow down the heart rate in case of atrial fibrillation, or to reduce the risk of ventricular fibrillation in case of ventricular arrhythmias. Drugs commonly used include: digoxin, diltiazem, amiodarone, mexiletine, atenolol and sotalol.

### **Nutritional support**

The goal of nutritional support is to provide moderate salt restriction to prevent fluid retention. Many renal diets can achieve that. Other supplements such as omega 3 fatty acids (to reduce the production of cytokines involved in cardiac cachexia), taurine, carnitine can also be provided in diets such as Early Cardiac Support by Royal Canin.

## Prognosis

The prognosis is quite variable and breed-dependant. Irish Wolfhounds may do well for years, while Dobermans usually succumb quickly to their disease. In that breed, the survival after onset of CHF was < 60 days before Pimobendan was available. It is now 6-8 months. For most of the other breeds, the average survival after onset of CHF is 8-10 months on treatment (Figure 9).

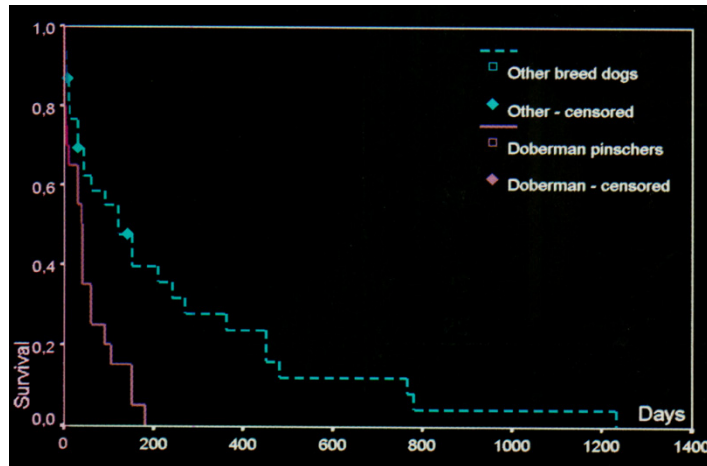


Figure 9: Survival curves of dogs with DCM (from Petric AD et al, J Vet Cardiol, 2002)

### Bibliography

Sisson DD, Thomas WP, Keene BW. Primary myocardial diseases of the dog. In Ettinger SJ, Feldman EC (eds). Textbook of Veterinary Internal Medicine. Philadelphia, WB Saunders (5<sup>th</sup> ed): 874-895.

Keene BW, Panciera DP, Atkins CE et al : Myocardial L-carnitine deficiency in a family of dog with dilated cardiomyopathy » JAVMA, 1991 : 5 : 134

Kittleson MD, Keene B, Pion PD et al « Results of the Multicenter Spaniel Trial (MUST) : Taurine and carnitine responsive dilated cardiomyopathy in American Cocker spaniels with decreased plasma taurine concentration » J Vet Intern Med 1997 : 11 : 204-211

Pion PD, Keene BW, Miller M, Fox PR : « Nutrition and management of cardiovascular disease » in Fox PR, Sisson D, Moise NS (eds); « Textbook of canine and feline cardiology », WB Saunders, Philadelphia, 1999; 739-755

Kramer GA, Kittleson MD, Fox PR et al : « Plasma taurine concentration in normal dogs and in dogs with heart disease » J Vet Intern Med 9; 253, 1995

Keene BW. Kittleson MD, Rusj JE et al : « Myocardial carnitine deficiency associated with dilated cardiomyopathy in Doberman Pinschers » Abstract, Proceedings of the ACVIM, 1989

Sanderson SJ, Osborne CA et al : « Evaluation of urinary carnitine and taurine excretion in 5 cystinuric dogs with carnitine and taurine deficiency ». J Vet Int Med 2001, 15 : 94-100

Dr. Eric de Madron, DMV, Dipl. ACVIM (Cardiology)  
and dipl. ECVIM (Internal Medicine)